

Minimally Invasive
ORTHOPEDIC SURGERY



www.ovrs.com | info@ovrs.com
248-334-6877

Oakland Veterinary Referral Services has long been considered a leading center of specialty veterinary care in the Midwest.

As a result of ongoing expansion, we now have one of the most comprehensive veterinary specialty facilities in the country, and are open 24 hours every day for emergencies.

When your pet needs the expertise of a specialist, OVRS is the world-class choice for your pet's care. Our veterinary specialists are board-certified in their specialties, and they are supported by a highly trained staff of licensed veterinary technicians and other caring professionals.

Our expert professionals, advanced technology and wide range of treatment options all contribute to excellent veterinary care. However, we realize the ultimate satisfaction of our clients depends on the excellence of our client service. We are proud to have earned the confidence, trust and respect of thousands of local veterinarians and pet owners alike by offering exceptional care and outstanding services in a nurturing environment.

OVER 25 YEARS OF Setting the Standard

30,000 Square Foot Hospital
Over 20 Board-Certified Veterinary Specialists
and Emergency Veterinarians

Renowned Expertise

Diversely Trained Clinicians
Extensive Referring Veterinarian Base
Exceptional Client Service and Satisfaction
On-Site Blood Bank
Newest Medical Advances and Techniques

Trusted Experience

Respected by Thousands of Referring Veterinarians
Advanced Medicine with Compassionate Care
Over 30,000 Patients Treated Annually

Partners in Care

Partnership Between You, Your Vet and Our
Emergency and Specialty Doctors
Extraordinary Care to Each and Every Patient
Regular Updates from Our Staff Doctors



(ar·thros·co·py):

Examination of the interior of a joint using an endoscope that is inserted into the joint through a small incision.

Minimally invasive surgery has been the standard of care for human surgery for many years, and has recently become more widely accepted in veterinary medicine. It allows for a minimally invasive approach to the joint, visualizing intra-articular structures including ligaments, cartilage, and menisci. It allows surgeons to better visualize and diagnose joint problems. Joints that can be explored arthroscopically include the stifle, shoulder, and elbow; the tarsus and hip in select patients.

(fluo·ros·co·py):

Examination by means of a fluoroscope, a radiologic instrument equipped with a fluorescent screen on which opaque internal structures can be viewed as moving shadow images formed by the differential transmission of x-rays through the body.

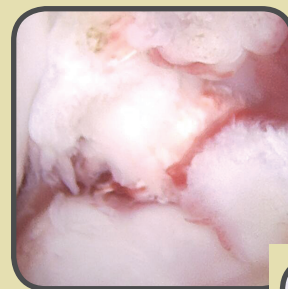
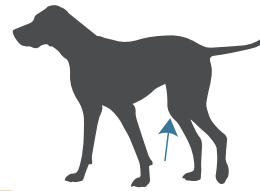
Minimally invasive techniques also include the use of fluoroscopy. This live action radiography can be useful in fracture repair and luxation reduction, particularly sacroiliac luxations. Fluoroscopy allows for small incisions to be made around the fracture or pelvis, reduction without disruption of the fracture callus/hematoma and associated vasculature, and stabilization with limited implants.

These have the benefits of: minimal tissue disruption, maintenance of fracture callus to promote early bone healing, maintenance of vascularity associated with bone fragments, and reduced morbidity from limited soft tissue dissection.

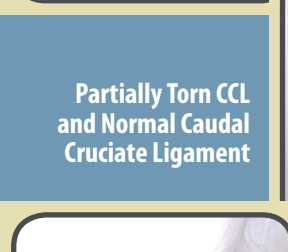
Fluoroscopy is also used in other sub-specialties of veterinary medicine, like airway evaluation, swallowing studies for dysphagia, portal vein angiography, contrast evaluation of the urinary tract, and stenting.

STIFLE (knee)

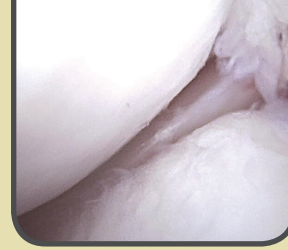Arthroscopy of the stifle has been shown to allow better visualization and diagnosis of meniscal tear compared with arthrotomy. Meniscal tears and releases can be treated arthroscopically as well, preventing the trauma and healing time of a traditional arthrotomy. Additionally, cranial cruciate ligament tears, OCD lesions, and other pathology can be evaluated and treated arthroscopically. Typically, we perform stifle arthroscopy immediately prior to performing a tibial plateau leveling osteotomy (TPLO), confirming the cranial cruciate ligament rupture and meniscal status before continuing with the TPLO.



Torn CCL Fibers



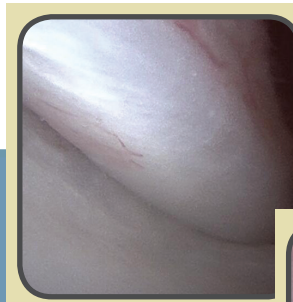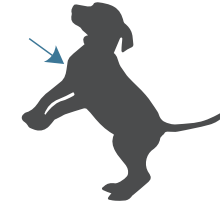
Partially Torn CCL and Normal Caudal Cruciate Ligament



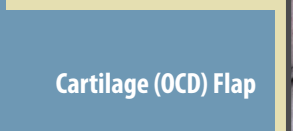
Normal Lateral Meniscus with Torn CCL Fibers on Right Side

SHOULDER

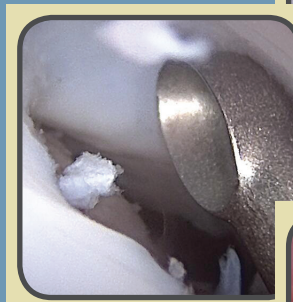Arthroscopy of the shoulder allows a minimally invasive technique to evaluate the biceps tendon and for OCD lesions. Both a biceps release and cartilage debridement can be performed using the arthroscope, allowing for only 2-3 very small incisions. This technique has improved accessibility and visualization of the caudal humeral head, where OCD lesions are typically located. Additionally, arthroscopy has been used to assist in shoulder instability repair.



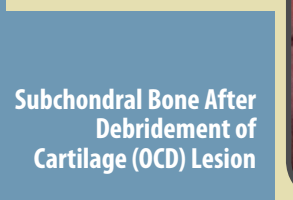Normal Biceps Tendon



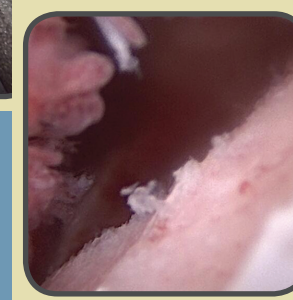
Cartilage (OCD) Flap



Curetting OCD Cartilage Flap



Subchondral Bone After Debridement of Cartilage (OCD) Lesion



Cartilage Erosion/ Eburnation along Ulna, Looking Proximally Towards Anconeal Process

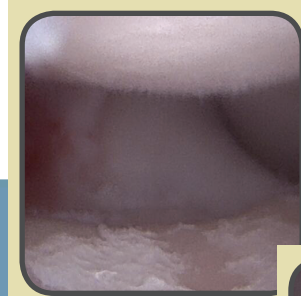
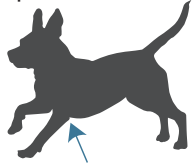
TARSUS (ankle) / HIP

Tarsus / Hip Arthroscopy can be used to evaluate the tarsal and coxofemoral OCD lesions, as well as aiding in a minimally invasive reduction of hip luxation and toggle pinning in select patients.

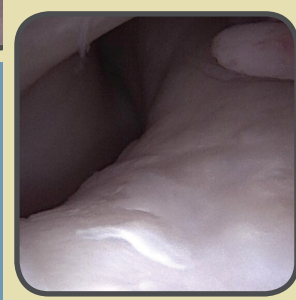

ELBOW

Similar to the shoulder, arthroscopy provides a minimally invasive way to evaluate the cartilage and bone structures of the elbow. Elbow problems can be debrided and treated with this approach, preventing a large arthrotomy, and allowing improved access and visualization of otherwise small structures. Even in cases of more severe progression of osteoarthritis and erosion of the medial compartment, arthroscopy can aid in both diagnosis and treatment. Additionally, biceps release can be performed at the elbow, if indicated.

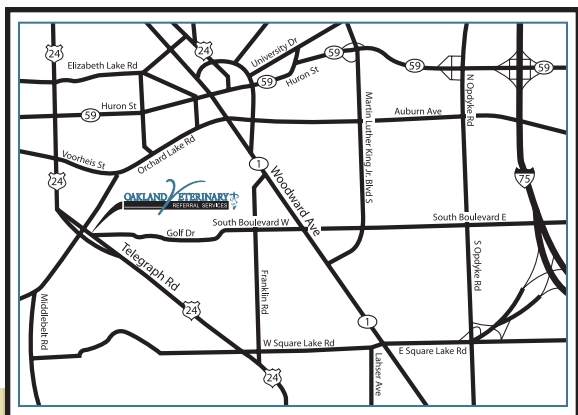
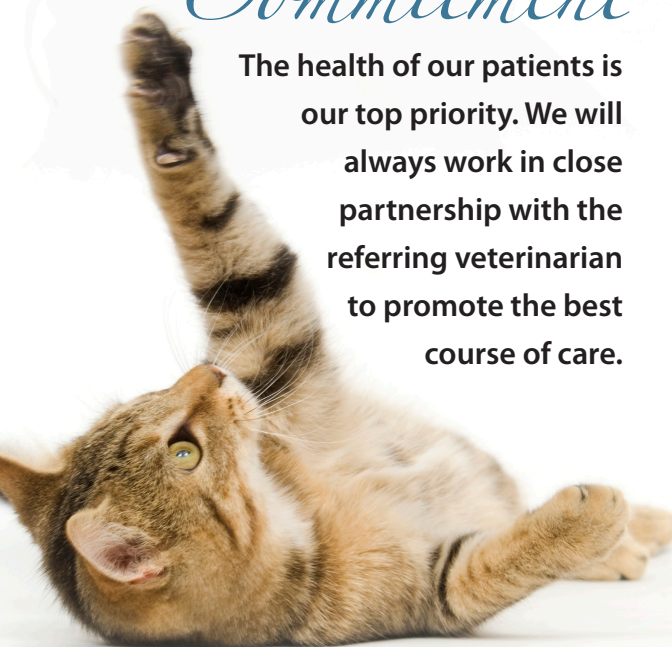

Cartilage Erosions along Ulna and Humerus after FCP



OUR *Commitment*

The health of our patients is our top priority. We will always work in close partnership with the referring veterinarian to promote the best course of care.



1400 South Telegraph Road
Bloomfield Hills, MI 48302